

# Prolonged Ex Vivo Lung Perfusion (EVLP) in an uncontrolled cardiac dead donor: a case report

Dott.ssa ELENA CHIODAROLI (1), Dott.ssa GIULIA MARIA RUGGERI (2), Dott. LUIGI VIVONA (1), Dott. JACOPO FUMAGALLI (2), Dott.ssa FRANCESCA GORI (2), Prof. GIUSEPPE CITERIO (3), Dott. ALESSANDRO PALLESCHI (4), Prof. LORENZO ROSSO (4)(5), Prof. MARIO NOSOTTI (1)(4), Prof. GIACOMO GRASSELLI (1)(2), Prof. ANTONIO MARIA PESENTI (1)(2), Dott. ALBERTO ZANELLA (1)(2)

(1) Department of Pathophysiology and Transplantation, University of Milan, Via F. Sforza, 35, Milano, Italia.

(2) Department of Anesthesiology, Intensive Care and Emergency Medicine, Fondazione IRCCS Ca' Granda, Ospedale Maggiore Policlinico, Via della Commenda, 16, Milano, Italia.

(3) University of Milan-Bicocca, Piazza dell'Ateneo Nuovo, 1, Milano, Italia.

(4) Thoracic Surgery and Lung Transplant Unit, Fondazione IRCCS Ca' Granda, Ospedale Maggiore Policlinico, Via Lamarmora, 5, Milano, Italia.

(5) Department of Health Sciences, University of Milan, Via A. di Rudinì, 8, Milan, Italia.

Argomento: Caso clinico

## Introduction

Ex vivo lung perfusion (EVLP) is an established technique to preserve, evaluate and recondition lungs from marginal donors. The possibility of prolonging lung perfusion, for different reasons, is becoming of growing interest.

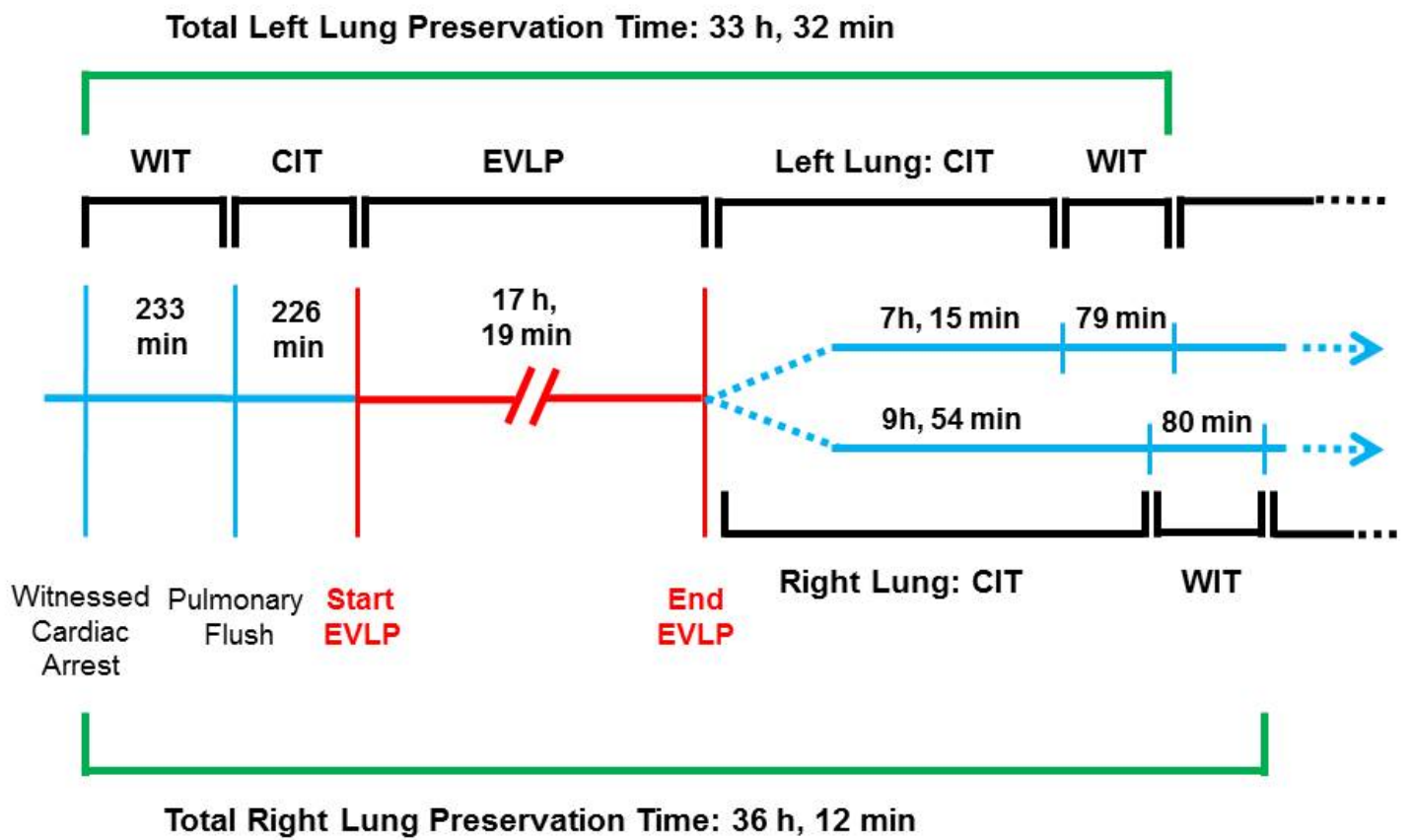
## Case report

We report a case on the use of a prolonged EVLP to deal with a diagnostic problem related to the donor. The local organ procurement organization (San Gerardo Hospital, Monza) proposed the lungs of a 57-year-old non-smoker donor who died because of a witnessed out of hospital cardiac arrest (Maastricht category II). An open lung strategy with recruitment manoeuvres and protective mechanical ventilation was applied to the donor (see Figure 1 for donor's lungs management).

Once transferred to Fondazione Ca' Granda, we performed a normothermic EVLP, run with a blood flow of 40% estimated cardiac output, open atrium and low hematocrit (mean 13%) technique. Because of a diagnostic oncologic doubt in the donor, we decided to prolong EVLP waiting for a definitive histological result. After 17 hours and 19 minutes, oncologic diagnosis was ruled out and lungs were deemed suitable for transplantation: PaO<sub>2</sub>/FiO<sub>2</sub> was 577 mmHg, lung compliance 96 ml/cmH<sub>2</sub>O and pulmonary vascular resistances 75 dyn\*sec/cm<sup>5</sup>. Lungs were proposed to a recipient, with cystic fibrosis (lung allocation score, LAS, 37), who consented to the transplant. The recipient underwent mechanical ventilation for 2 days, and was discharged from ICU after 3 days and at home after 21 days from transplant. He is now in good conditions (FEV1 55%).

## Conclusion

The reported case demonstrates that EVLP could be successfully prolonged to deepen donor's medical history. EVLP allows to optimize the donation process and extend lungs evaluation, particularly relevant in uncontrolled cardiac dead donors. Prolonged EVLP would potentially expand the pool of organs available for transplantation.



**Figure 1. Donor's lungs management : timeline**

WIT, warm ischemia time; CIT, cold ischemia time; EVLP, ex vivo lung perfusion.